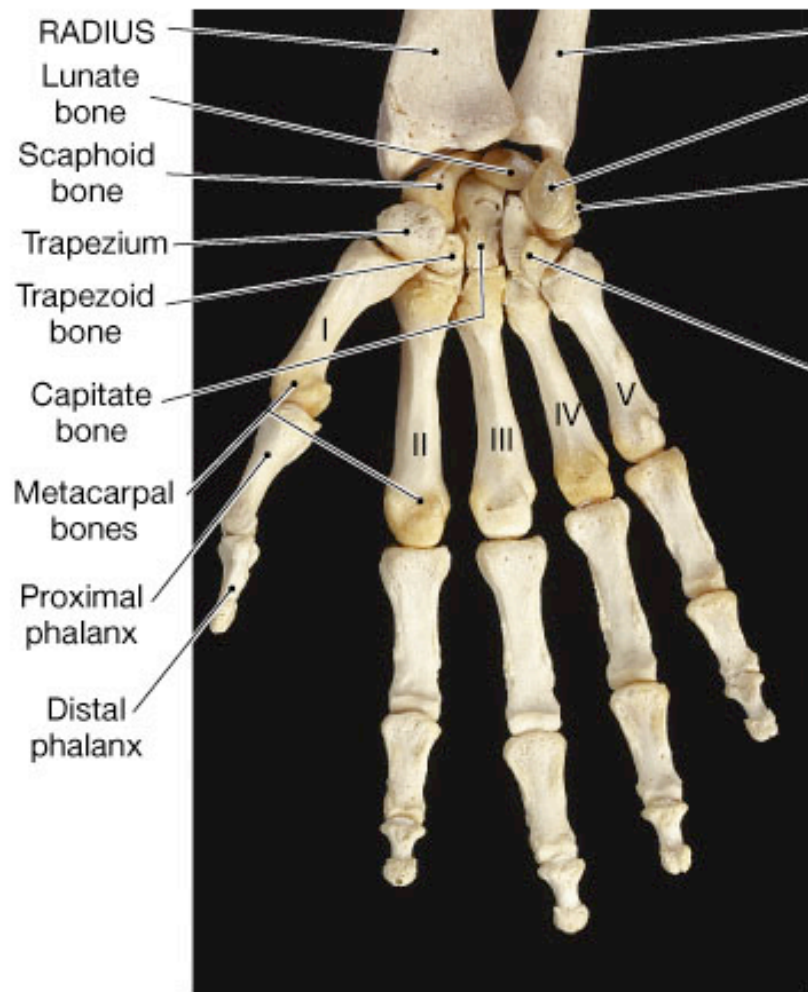


# PHYE 281 - Applied Kinesiology

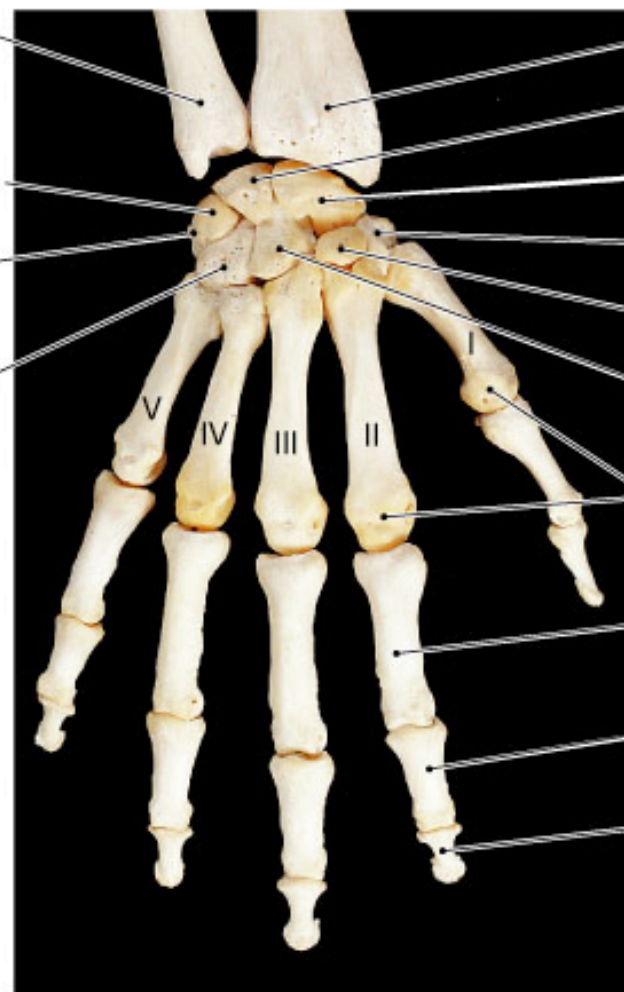
Image Bank and Study Sheets  
For Lecture 7 - The Wrist and Hand

Kevin Petti, Ph.D.  
Department of Natural Sciences  
Health, Exercise Science and Nutrition  
San Diego Miramar College



**(a) Anterior view**

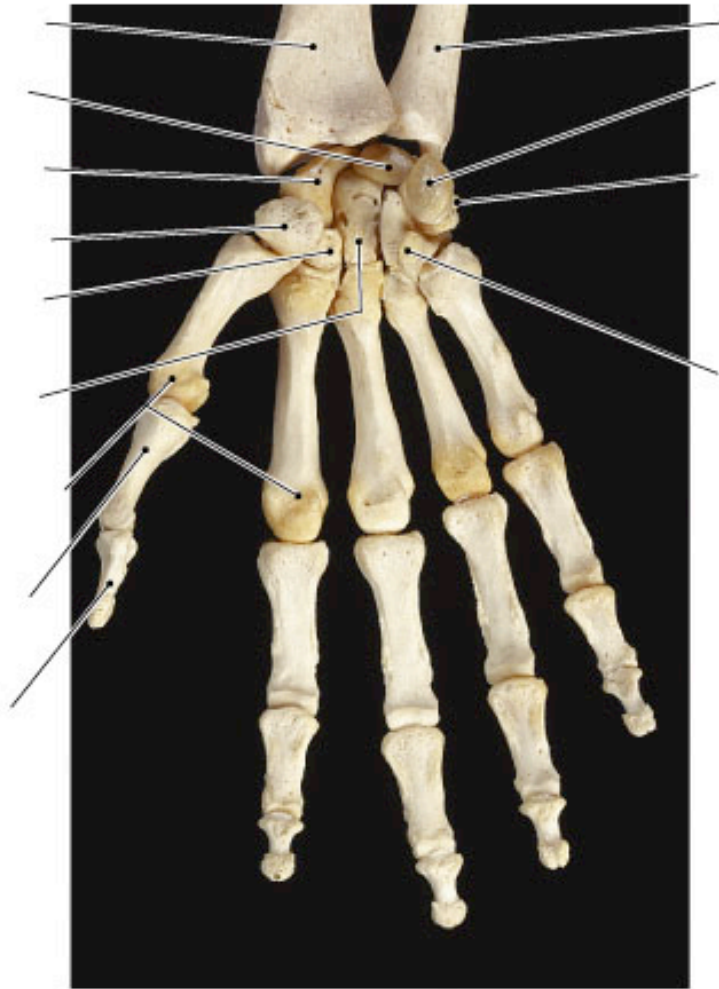
ULNA  
Pisiform bone  
Triquetrum  
Pisiform bone  
Hamate bone



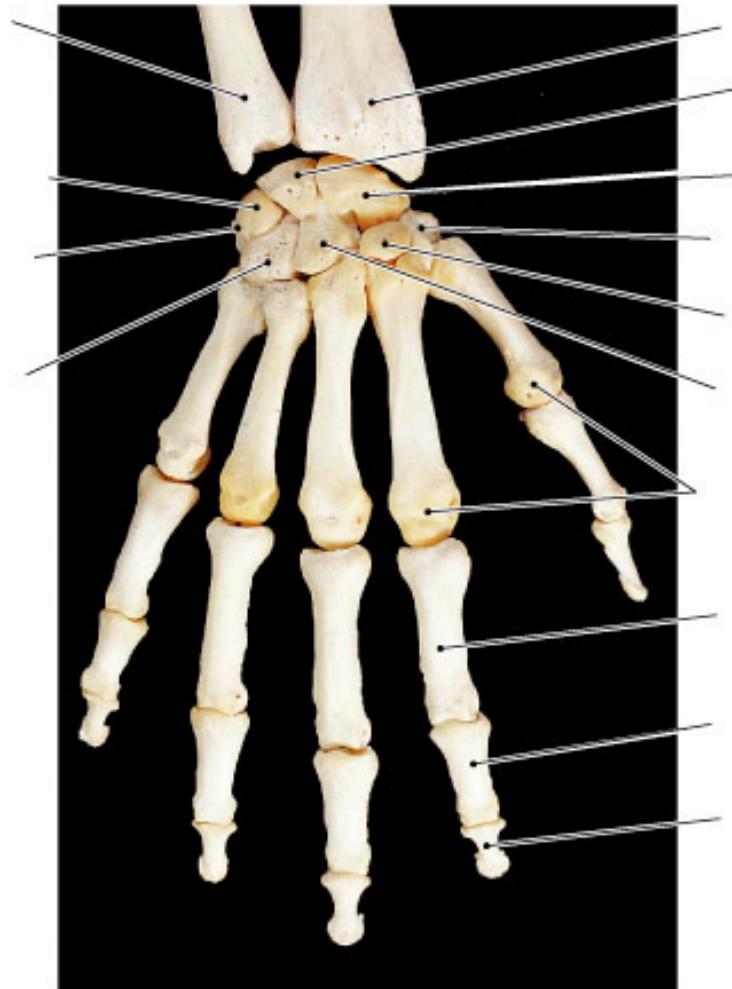
**(b) Posterior view**

RADIUS  
Lunate bone  
Scaphoid bone  
Trapezium  
Trapezoid bone  
Capitate bone  
Metacarpal bones  
Proximal phalanx  
Middle phalanx  
Distal phalanx

Copyright © 2004 Pearson Education, Inc., publishing as Benjamin Cummings.

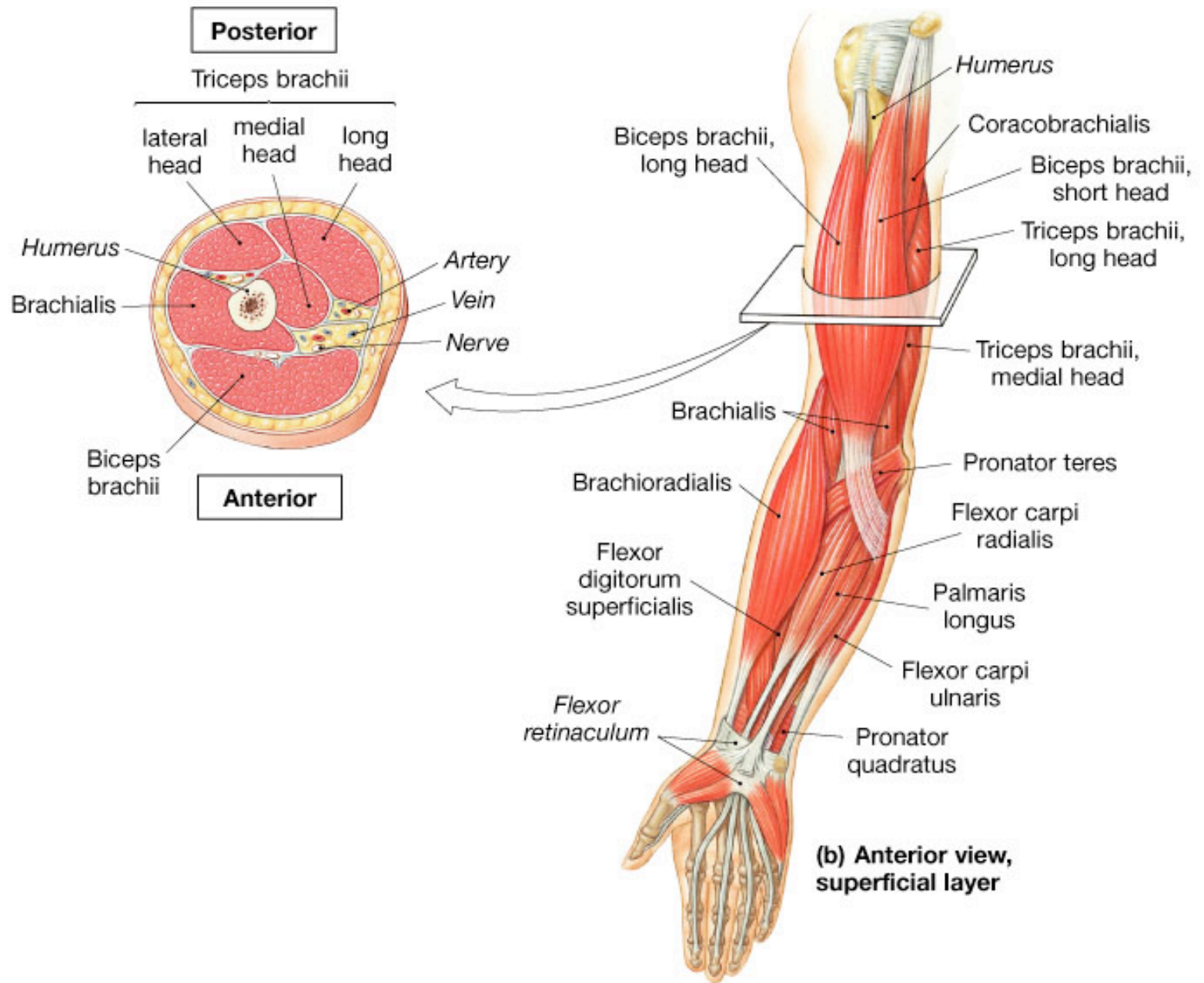


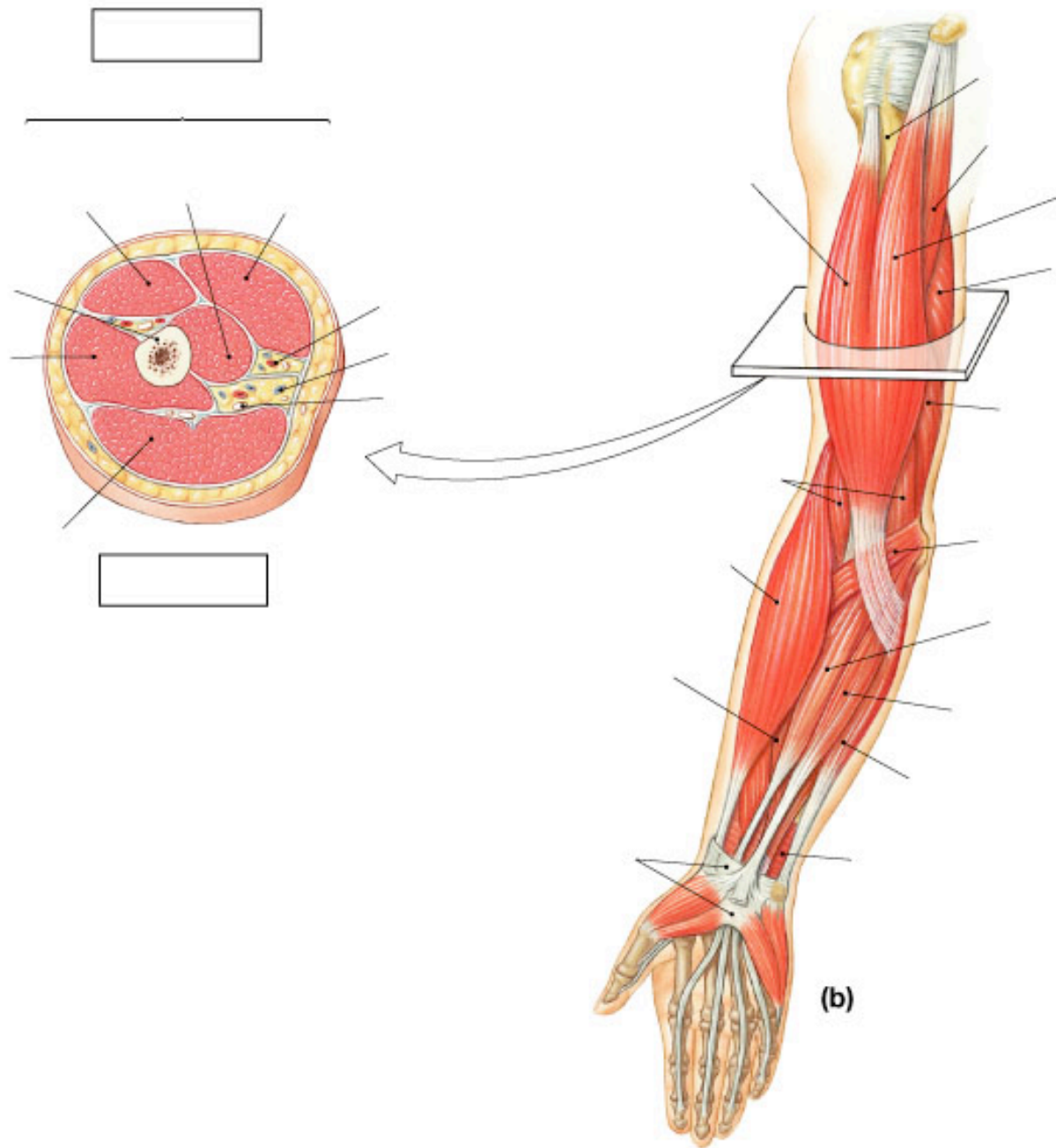
(a)

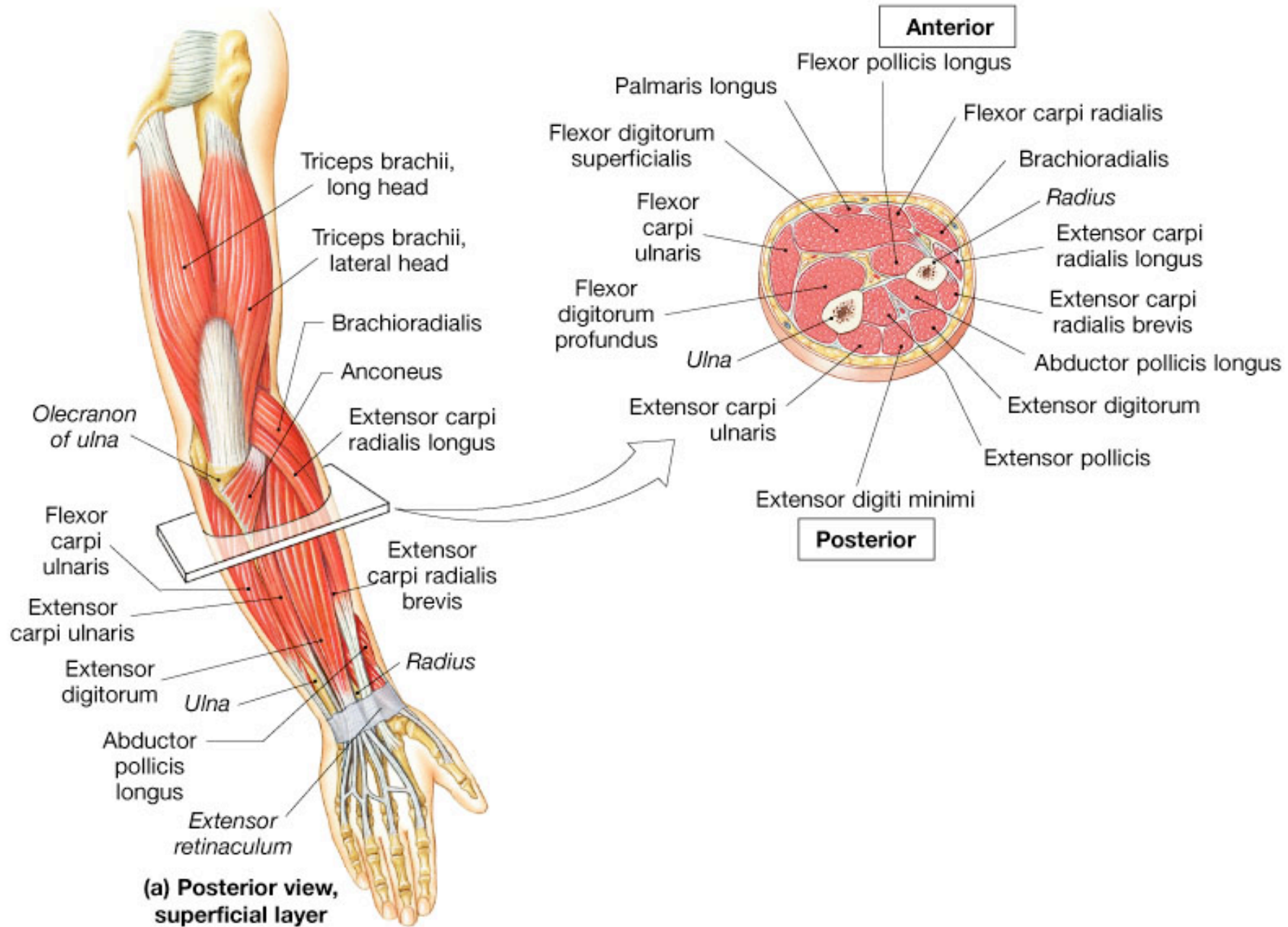


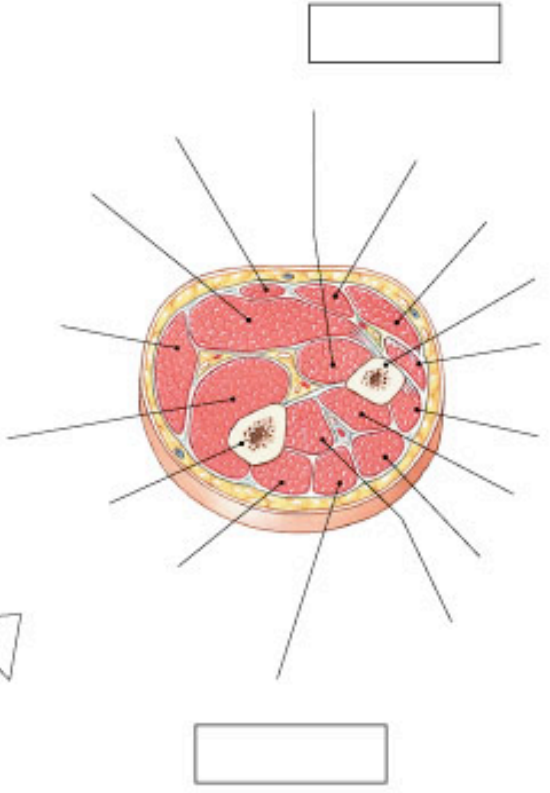
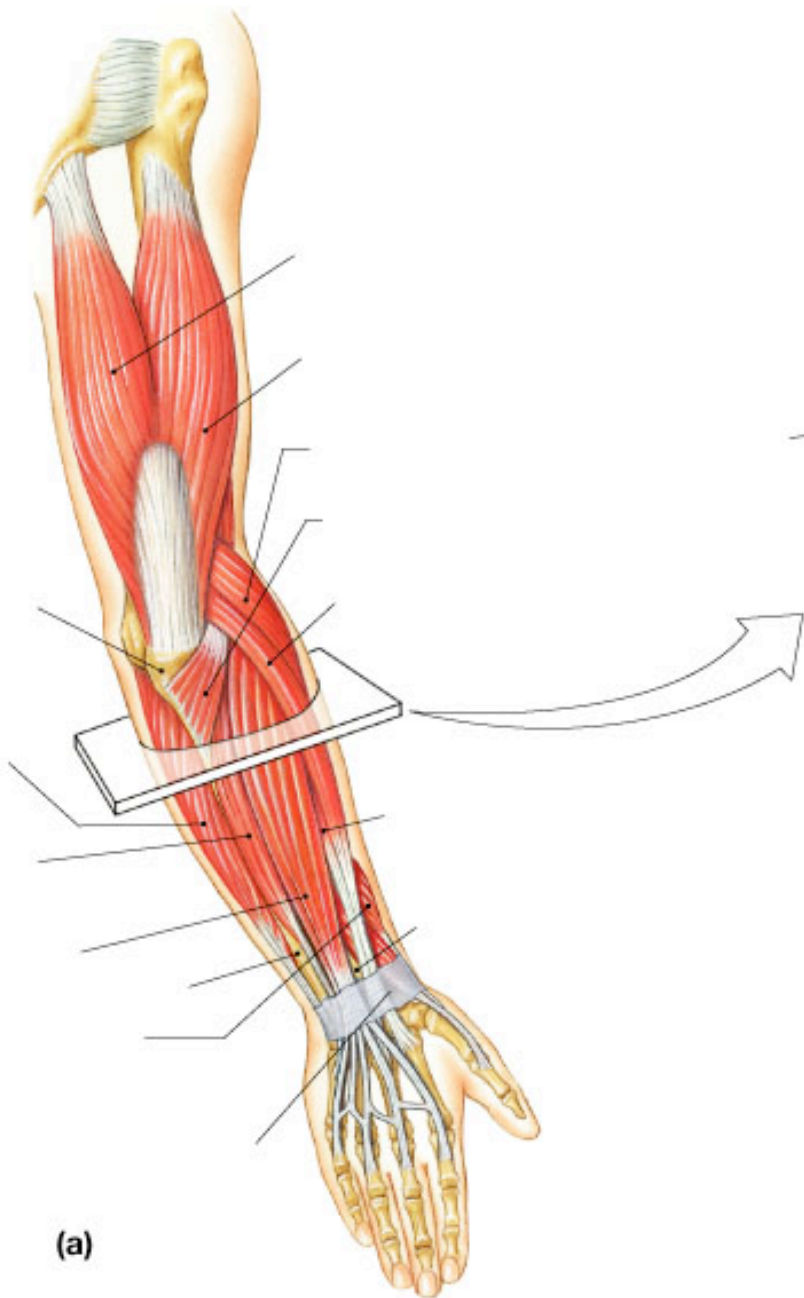
(b)

Copyright © 2004 Pearson Education, Inc., publishing as Benjamin Cummings.









**(a)**